

# Acupuncture in Severe Chronic (Allergic) Obstructive Pulmonary Disease (COPD) in Horses (218 cases)

Uwe Peterman, DVM  
Schmale Strasse 20, Melle 49326 GERMANY

## Summary

Allergy, as a form of immunodeficiency, is caused by exhausting Kidney energy. This can occur when the amount of single factors, that the body has to fight against in its daily life, becomes too big. The result is that the former superficial Biao- illness goes deeper and deeper inside the body and becomes a Li-illness. COPD in horses is such a Li-illness. Controlled acupuncture is shown as a holistic concept to help the body to relieve itself from the vicious allergic circle it is captured in, and return to normal.

Using laser acupuncture exclusively, 218 horses with severe or even extreme COPD were treated. No other medicinal or alternative therapies were administered. All patients had been previously treated over a lengthy period (3 months to 10 years) with conventional therapies such as corticosteroids, clenbuterol, drugs for secretion removal, hyperinflation, inhalation etc. without success. The acupuncture lasers used were 904nm infrared pulsed lasers with 60 and 90 watt peak pulse power with an impulse width of 200 nsec. As pulse frequencies, those from Nogier and Bahr (between 100 and 20,000 Hz) were used. The horses were treated 4 - 10 times on each point for 30 sec. (few horses were treated more than 10 times, on average 5-6 times). The interval between treatments was 4-7 days. In most of the patients (n=148, 68%) a clear spontaneous reaction could already be seen during the first session. The horses were able to breath deeper and remove secretion in a manner similar to that of infusion therapy. Thirty three patients that had not improved after 3 or 4 treatments were treated by laser on marked points by their owners every day for 2 - 3 weeks with a 30mW continuous laser, 30 sec. on each point. After conclusion of the treatment, 143 horses (66%) appeared to have been cured. In other words, there was no more coughing, no more difficulty in breathing; the respiratory tract was clean and showed no signs of inflammation. The horses seemed to be in excellent physical condition. Forty-eight horses (22%) were much better and had no more problems with their stamina, but sometimes had a slight cough while being ridden. Twenty-one horses (10%) were also better than before and could be ridden, but their stamina was not completely restored and they were still coughing so that the result was not deemed satisfying. Only 6 horses (2.8%) showed no signs of improvement following the treatment.

**Keywords:** laser, acupuncture, horse, COPD

## **Introduction**

In this paper I will describe my personal perceptions and experiences, inspired by many authors, in regard to the exploration of the origin of immune- deregulations leading to chronic allergic disease, especially COPD in horses.

In the present medical system it is mostly attempted to treat a single symptom without taking into consideration the original connectional factors which have caused their source. In most cases, this leads to a reduction of regulation within the entire organism by the treatment with antibiotics in acute and corticosteroids in chronic disease. I personally consider this to be an unsatisfying, often ineffective and frequently harmful form of treatment when used in a long term therapy. Antibiotics and corticosteroids should only be given after serious consideration. In my patients I stopped all therapies and medications before starting acupuncture treatment every time, even in cases with serious inflammation and a high fever. The following is a description of the use of a holistic therapy, utilizing the approach of controlled acupuncture, in the highly effective treatment of COPD.

## **Patients in this study**

All 218 horses used in this study were suffering from severe or extreme COPD. Only patients with pronounced dyspnea in the resting state and an extended lung percussion area at least 4 fingers wide were selected. All horses had been treated with the usual allopathic methods: mucolytics, bronchodilators, corticosteroids, inhalation using an ultrasonic mist generator and, to some extent, with hyperinfusion therapy (DEEGEN, E. LIESKE, R. and FISCHER, J. 1980, DETLEF, E., KÖHLER, L. and ALLMELING, G. 1982, DEEGEN, E. 1988) over a prolonged period (2 months to several years) without success. The study involved 14 stallions, 84 mares and 120 geldings. The horses were between 1 and 30 years of age (average age 12.3 years). In 71 of the horses (33%), the stabling conditions had already been optimised over a longer period of time (sawdust on the floor, silage feed, hay soaked in salt water, open stabling, access to pasture all the year round).

## **Examination Procedure**

History from the owner included duration, course and seriousness of the illness, stabling and feeding conditions, quality of the feed, and previous treatment. The horses were examined externally (frequency and depth of breathing, type of breathing, breathing through the nostrils, and nasal discharge). The entire body was also examined for any scars of substantial size. Finally, a thorough auscultatory examination and a percussion of the lung area were carried out. In the process, attention was paid to the lung percussion area and to any areas of unusually loud resonance. In the initial examination of all patients, except those suffering from extreme dyspnea, breathing stimulation or inhibition was used before auscultation. In the post-examination, an inhibition of the breathing was carried out for about 45 sec. followed by an auscultation (but not for the 4 patients which showed no improvement). A bronchoscopic examination was carried out on some of the patients (n=55) as a supplement to the clearly identified clinical findings. Viscosity, amount and distribution of the secretion, mucous membrane edema in the neighborhood of the bifurcation,

and reddening of the mucous membrane were assessed. Subsequently, the acupuncture diagnosis was carried out using the method of the “*Deutsche Akademie für Akupunktur und Aurikulomedizin*” (BAHR, F. 1997, PETERMANN, U. 1999) to find the optimum acupuncture points for the treatment. This method not only helps detect any perturbative field and pollutions, it helps to make a consistent and reproducible diagnosis so that the points, at which the therapy is to be applied, can be determined.

## Therapy

For the individual treatment of each patient, each of the points diagnosed by the controlled acupuncture was treated with an acupuncture laser for 30 sec. The following points were most often found: BL 13, (Shu point of the Lung meridian), BL 14, (Shu point of the Heart/sexuality meridian), BL 17, (Influence point of the Diaphragm), LU 7 and KI 6 as cardinal point pair, BL 40, (allergy point and histamine point of the ear acupuncture), BL 23, (Shu point of the Kidney meridian), CV 17 (respiratory alarm point of the three heaters) and St 40, (mucus dissolving point, beta-agonist point), LIV 13 (ACTH point) as well as the points TH 5 and KI 3, important for all inflammatory processes, demarcation and inheritance energy in the organism. In addition, the individual scars and periodontitis points found during the acupuncture diagnosis were also treated with the laser, sometimes up to 5 minutes per point.

The treatment of all acupuncture points were carried out with a 60W and a 90W impulse- acupuncture laser (Reimers and Janssen Company) for 20 - 30 sec. per point. These are diode impulse- lasers with a wavelength of 904 nm and pulse duration of 200 nsec.

Essentially, the frequencies A, B and C of the frequency bands according to NOGIER (292, 584, 1168 Hz) as well as the frequency 5 (frequency for the cardinal points) and 7 (for treatment of *hidden* tooth- foci), from the frequency bands according to BAHR (9592, 149.5 Hz) were used.

Four to twelve treatments were carried out at intervals of 4 to 7 days (a few patients up to 30 treatments, on the average 5-6 treatments). Regardless of the degree of positive response to treatment, fifty patients were again experiencing very serious breathing difficulties by the next treatment date. In 33 of these 50 patients, the points were marked by hair cut at each point. They were then sent home where the owners themselves, radiated each point daily over a 2-3 week period. Each treatment was for 30 sec. using a Handylaser (Reimers and Janssen Company and Schwa-Medico Company, both 50 mW continues- wave- lasers, wavelength 820 nm).

One hundred and seventeen patients which, before the start of the treatment, had not enjoyed any improvement in husbandry or had again been neglected, were kept in these same conditions during the therapy. On the other hand, the conditions of 30 patients were optimised during the therapy. (see list of patients)

## Results

With very many patients (n=148), significant reactions could be observed during the first treatment (47 patients with very good and 101 patient with good reactions). An increase in the depth of breathing, sometimes quite significant, was a regular occurrence when the point BL 17 (Influential point for the

Diaphragm) was treated. This was often accompanied by an increase in coughing. With most of the patients, it was noticeable that they took deep breaths a number of times during the acupuncture - something not previously possible because of the obstruction. At the end of a treatment, or up to 10 minutes thereafter, a loud secretion mobilisation could be heard without the aid of a stethoscope in half of the patients, rather similar to that following a hyperinfusion therapy with frequent swallowing of secretion (19 patients extreme, 68 patients obviously, 26 patients moderate, 105 patients without changing). After the second or third treatment, in the case of some patients, the previous droning and rattling noises which could be heard by auscultation had completely and spontaneously disappeared.

At the end of the therapy, the following results had been achieved: 143 horses (66%) appeared to be in a healthy clinical condition, i.e. coughing no longer occurred at rest or motion and, after inhibition of breathing, no pathological breathing noises could be detected by auscultation. Also, the previous emphysema which had been determined by percussion had completely resolved. These horses were able to go back to full work again and showed no further cough symptoms. Of the 55 patients which underwent a bronchoscopic examination and which belonged to this group, 44 no longer showed any pathology. The next 48 patients no longer had any breathing difficulties and could be put back to normal work, but they coughed occasionally in the stable and on starting to work (22%). In 21 patients (11.9%), the ailments had improved and the horses could be put back to work again, to a certain extent, but coughing still persisted at the beginning of, and sometimes during work, so that one was not able to describe their state as satisfactory. Six horses showed no lasting improvement, although positive reactions were observed during their treatments. Of the 33 horses which were treated daily by their owners for a further 2-3 week period, 18 showed no clinical evidence of disease, 9 were “satisfactory” and 3 horses could be put back to work “with limitations”. Only 3 horses still had very serious breathing difficulties following this “intensive treatment” and were euthanized. One patient, that seemed to be clinically healthy at the end of the treatments, developed a very serious COPD again after only 3 weeks and the owner declined further treatment. One hundred and three horses were examined again after an observation period of between 6 months and 4 years (average of 1.8 years). All of these horses belonged to both of the groups in which a good or very good result was achieved. No worsening in the good condition of 56 of these patients was observed by the owners over the entire period. Three patients started to develop symptoms again after 6 months, in two patients after a year, in 4 patients after 3 years and in one patient after 4 years. After being free of symptoms for 10 years, following acupuncture treatment of extreme COPD, patient No. 97 had a reoccurrence of a similar COPD. After 3 treatments, the patient has now enjoyed 1 year of complete remission.

## **Case Studies**

These case studies are very interesting and helpful to show the procedure of controlled acupuncture and to see the connections between the disturbing foci as scars or unapparent sinusitis and allergic reaction.

### **Case Study No. 1**

Eight-year old, dark brown, Hanoverian mare with back problems and a medium degree of COPD.

The patient is extremely suitable for explaining the acupuncture procedure and disturbing focus principle, and to demonstrate how the treatment works. The horse's back problem was so extreme that this tournament horse had to be taken out of professional sport and could not even be ridden. The animal reacted to the slightest pressure in the area of the saddle and the kidneys. It also suffered with COPD with a corresponding reduction in stamina. Auscultation findings: distinct droning and rattling noises in the resting state, very clear droning and rattling noises following a Lobelin® injection (breathing stimulant). Bronchoscopic findings: abundant viscous mucus in the trachea, slight swelling and reddening of the bifurcation and main bronchi.

Acupuncture of the ear acupuncture points: The lung point (identical to body point LU 7) and the point of the plexus bronchopulmonalis (Lu 9), as well as the kidney point (KI 7) showed a distinct symptomatic improvement in the functioning of the lungs, in the sense of deeper inspiration and a relieved expiration. The droning noise disappeared. A distinct secretion mobilisation could be heard with the unassisted ear within a few minutes. The treatment of the symptoms of the back points (ear localisations cervical, thoracic and lumbar parts of the spinal column), as well as the thalamus point (identical with the point LI 4), brought no significant improvement on pain palpation. The acupuncture diagnosis detected a disorder in a two-year old badly scarred injury in the right forearm in the neighbourhood of the point LU 6. A two-minute treatment of the scar with the laser (freq. "A") was then performed. As a supplement, the thymus point (identical to body point TH 5) was treated with the freq. "5". Once this therapy was completed, the tenderness had spontaneously disappeared, even with heavy palpation pressure. Five days after this treatment, the old wound that had been closed for several years, opened up and fistulated. After a total of four laser acupuncture treatments, the back and lungs were without any clinical pathological findings. The horse was able to be put to work again and the fistula had healed.

## Case study No. 2

A 13 year old, grey, Arabian mare had been suffering for the last 9 years with COPD that had worsened so much in the last few years that the treating vet and the owner considered to perform euthanasia. Fortunately they referred the horse to me for acupuncture. On examination, we found a respiration rate of 56 breaths per minute with an extreme abdominal press on expiration. The nostrils were expanded to approximately the size of a hand and the eyes looked panicked (Fig. 1). One could hear a loud whistling sound up to 20 meters away from the patient. The lung percussion field had dilated to about two hands width and there was an overloud percussion sound to hear in this area. The following acupuncture points were found by RAC/VAS and were treated: LU 7, BL 13, BL 4, BL 17, BL 23, LIV 13, GV 17, ST 40, KI 3 and TH 5. In addition the acupuncture diagnosis, showed contamination with mercury, a disturbance in scar tissue underneath the carpus at LU 9. The LU 9 is the tonification and source-point of the Lung meridian and in ear acupuncture the point of the plexus bronchopulmonalis and therefore of great relevance. During the treatment of this scar with laser (radiation with 90 watt impulse laser, Fr. A from Nogier for about 3 minutes), one observed a relieved expiration and a deeper inspiration and a general improvement in the breathing. After the treatment with acupuncture the respiration rate had decreased 50% to 28 breaths per minute and the panicked look in the eyes and extreme nostril breathing had disappeared (Fig. 2). Seven

treatments of the same followed at 3-4 day intervals. The mercury pollution was addressed by giving the very high homeopathic dilutions of mercury (D10,000, D100,000 and D500,000 and D1,000,000). Four weeks later, after the seventh treatment, still at 3-4 day intervals, the horse was clinically normal and was capable again of galloping across the fields without any problem (Fig. 3). Unfortunately, after three weeks, despite the long distance of 500 km, the horse had to be returned to the clinic with the same symptoms. After six new acupuncture sessions, performed in the same way as before, the horse was again released, considered to be clinically normal again. After this treatment the horse has been healthy for an observation period of nearly 2 years. Also, the horse has not been in such a healthy condition, even in the ten years prior to the beginning of the illness.

### **Case Study No. 3**

A ten-year old, Trakehnian gelding was brought to acupuncture treatment after years of conventional treatment (Hyperinfusion, Dexamethasone, Clenbuterol, Bromhexin, Inhalation ultra sound fogged salt water). The horse had not been able to work for the previous six months, despite the following therapies. An infusion therapy had been carried out three weeks previously (4 days, 40 litre of saline solution intravenously in 3 hours per day). Also up to the day of the first acupuncture, the animal had inhaled corticosteroids daily. In addition, the horse had got daily doses of Beta-Mimetika and Sekretolytika (clenbuterol, acetylcysteine, bromhexin). The findings of the examination were as follows: violent dyspnea at rest, breathing: 36/min., intensely costal breathing with abdominal compression. In auscultation we heard extreme droning and rattling noises over the area of the main bronchi and trachea at rest. In percussion, we found an extended lung percussion area the width of more than a hand with unusually loud resonance. Bronchoscopic examination showed large quantities of highly viscous secretion in the trachea and in the main bronchi with swelling of the bifurcation trachea. The body temperature was normal, and there were no clinical signs of a sinusitis.

The acupuncture treatment took place at 2 -3 day intervals and on the points LU 7, KI 3, ST 40, BL 14, BL 17, BL 23, CV 17, LIV 13 and TH 5. The acupuncture examination detected a disturbing focus in the stomach meridian, in the area of the point ST 3, and pollution with mercury. The point ST 3 (non-IVAS location) lies at the root of the first molar tooth in the maxilla or at the sinus maxillaris over this tooth. The first molar of the upper jaw is known, to disturb directly at the point LU 1, the Mu point of the Lung meridian. The sinus maxillaris and the located point on the first maxillary tooth were treated using a laser area probe (8 x 10Watts impulse-diodes) for two minutes (Fig. 4). Within 10 minutes following the end of the irradiation, a recognisable deepening of the breathing could be ascertained. The breathing frequency decreased to 28 breaths per minute, the droning noise had become quieter but the secretion rattling noise had become louder because there was a lot of secretion mobilised by the treatment. Mercury was treated with very high dilutions (D10,000, D100,000, D500,000, and D1,000,000). But the patient's state improved only slightly in the following days of treatment. In spite of that, the owner was quite satisfied with the success. Because I was not content by the further improvement, for me it seemed sensible to break off the therapy. However, the owner insisted on further treatment and so we carried on. Because for me the clinically unapparent sinusitis, in the area of the left upper 1<sup>st</sup> molar tooth, had a key function in the therapy of this patient, I decided to extend the time of treatment with the laser- douche for this area from 2 to 10 minutes.

No distinct change in breathing could be determined during the acupuncture treatment and the first three minutes LLLT (Low Level Laser Therapy) of the sinusitis area which followed. But then, from the 4th to the 5th minute, the depth of the breathing suddenly increased vehemently and reached a state similar to that following an injection of breathing stimulants. The breathing became normal again about 5 minutes after the treatment was discontinued. On the following morning, the horse gave the impression of being free of symptoms for the first time. The breathing rate was around 8 breaths per minute (20-24 at all the days before the extended LLLT of the sinus maxillaris). Breathing was absolutely normal, no droning or rattling sounds could be heard following breathing stimulation with 10 ml Lobelin® (Lobelinhydrochlorid). The breathing got worse each time between treatments, at first 20 per minute in resting, then 16 and finally 8 to 12 per minute after further twelve treatments done in the same way. A large increase in the depth of the breathing was to be observed during the sinus treatment in the first ten succeeding treatments, although it was weaker from time to time. Even in this case, when an extraordinary large number of treatments had to be made, the effort was still justified as the horse had neither clinical nor bronchoscopic signs of illness at the end of the treatment and up to today, after a three-year period of observation, the horse has worked, been in very good condition and has returned to professional tournament sport (S-dressage). For me this patient was one of the most convincing cases in my life, showing the direct influence of disturbing focus in failure of immune regulation leading to allergy.

## **Discussion**

These few examples are like the hundreds of other cases I have seen that show a direct connection between laser therapy of the disturbing focus and the clinical reaction of the patient. The results show that acupuncture, as a regulating autonomous nervous system therapy, in connection with the treatment of the disturbing focus, is extremely suitable to treat irregularities. It is especially valuable because all patients had a very severe and chronic form of COPD which had already been treated for a long time without success with common treatment. In most of these cases, it was to see very clearly that a combination of pollutions, genetic weaknesses, living conditions, disturbing focus, as well as their feed back to organs and the organic systems, can start a negative chain effect within the organism causing a never ending circle of chronic illness.

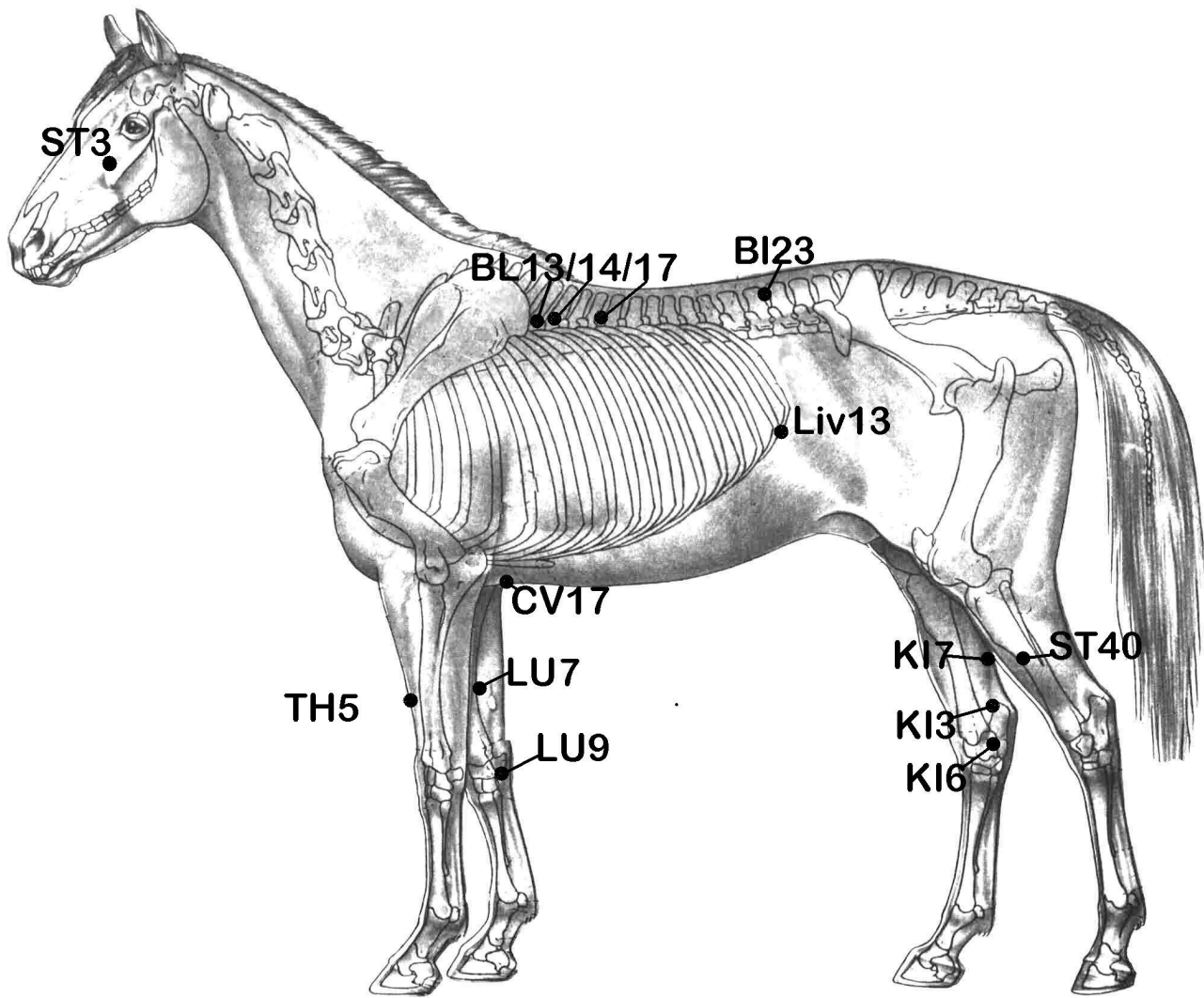


Fig. 1



Fig. 2



Fig. 3

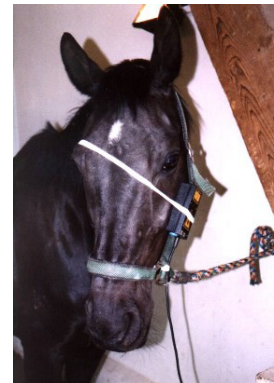


Fig. 4



## Literature

1. Bahr, F. (1997) *Scriptum Systematik und Praktikum der wissenschaftlichen Akupunktur für weit Fortgeschrittene und Experten*. Eigenverlag, München 1997
2. Bahr, F. (2001) Resonanzen von Kalifornischen Blütenessenzen zu Ohrlokalisationen und konkreten Akupunkturpunkten (EAA-Jahreskongress Davos 2001)
3. Bergsmann, O. (1977) : Die biokybernetische Wirkung der Akupunktur im klinischen Versuch. *Dtsch. Ztschr. f. Akup.* 5, 131ff
4. Bergsmann, O. (1980) : Pathogenetische Aktivität der Störfelder. *Der informierte Arzt* 20, 41-48
5. Bushe Centmayer, K. (2001) Einsatz von Kalifornischen Blütenessenzen in der kontrollierten Akupunktur (EAA-Jahreskongress Davos 2001)
6. Kellner, G. (1963) : Wirkung des Herdes auf die Labilität des humoralen Systems *Öst.Z. Stomatol.* 60, 312
7. Kellner, G. (1965): Nachweismethoden der Herderkrankungen und ihre Grundlagen. *Therapiewoche* 15, 1267-1274
8. Kellner, G. (1965): Zur Histochemie der Narbe. *Hippokrates* 36, 777-785.
9. Kellner, G. (1979) : Der Herd in experimentell-histologischer Sicht. *Österr.Ärztztg.* 34, 933 - 935
10. Kluger, L. (1991) : Odontogene Störfeldmöglichkeiten. In: *Österr. Med. Ges. f. Neuraltherapie - Regulationsforschung* (Hrsg.): Herd-Störfeldgeschehen. *Facultas, Wien* 40 - 46
11. Naber, M. (2001) Erkrankungen der Mitte und ihre Bedeutung in der Praxis. *Der Akupunkturarzt Aurikulothérapeut.* 1, 3-5
12. Petermann, U. (1997) Auffinden von Störfeldern mit Hilfe der kontrollierten Akupunktur. *Ganzheitliche Tiermedizin* 1999; 13; 10-13
13. Petermann, U. (2000) Laser Therapy in Veterinary Medicine. *Proceedings of IVAS World Congress 2000, Vienna*, 144-148
14. Stacher, A. (1965) Die Therapie der Herderkrankungen. *Therap.woche*, 15, 1278-1284.
15. Strittmatter, B. (1998) Das Störfeld in Diagnostik und Therapie.
16. Tucker, D. (1990) Laser and Electrodiagnostic Techniques for the Isolation and Treatment of Odontogenous Foci *American Journal of Acupuncture*, Vol 18, No.4,
17. Zilk, A. (1997) Personal Information